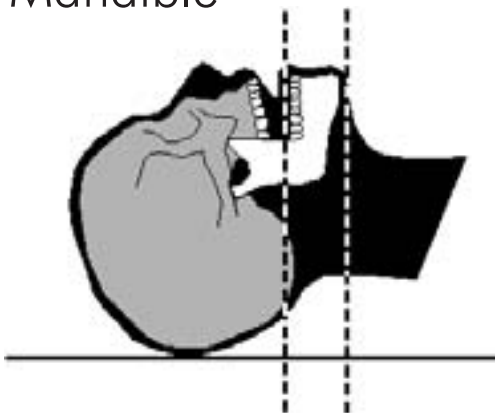




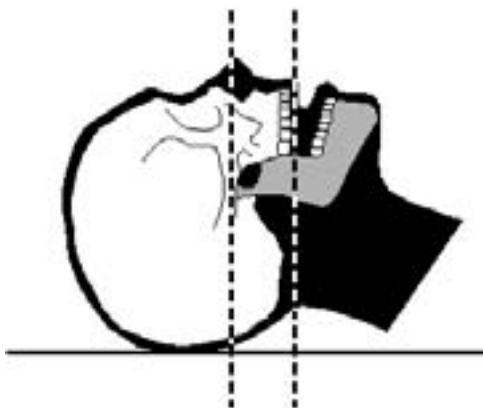
Scanning Protocol for SimPlant and SurgiGuides

Requested alignment and image range

Mandible



Maxilla



Scanning parameters

Matrix	512 x 512
Field of View	Between 140 and 170 mm
Slice thickness	1.0 mm
Feed per rotation	1.0 mm
Reconstructed slice increment	1.0 mm
Reconstruction algorithm	Bone or high resolution
Gantry tilt	0°

Remove metal dentures, prosthesis or jewelry
Scan teeth and scan prosthesis
Only the axial images are required



Scanning Protocol for SimPlant and SurgiGuides

This document describes the guidelines for a CT scan that is taken for the purpose of ordering a SimPlant project and/or a SurgiGuide from Materialise. This protocol is preferably transferred to the radiology department, together with the scan order.

SimPlant* is the dental planning software of Materialise, which uses high quality CT images for the preoperative planning of dental implants. The image quality you experience within the SimPlant software depends on the capability of the CT scanner to produce thin-sliced, high-resolution axial images. It is also essential to the quality of the images, that your scan site is provided with and properly follows this scanning protocol.

With high quality images, the preoperative plan can be made with greater ease and accuracy. At Materialise, SurgiGuides are designed and generated based on both the CT images and the preoperative plan. SurgiGuides are drill guides that indicate both the position and orientation of the planned implants. They are used to transfer the plan to surgery and guide the surgeon's drill according to the preoperative plan.

Using this scanning protocol as a guideline will not only result in a more accurate plan, but will assure a precise fit of the SurgiGuides on the jaw, and in the end, a pleased patient with nicely positioned teeth.

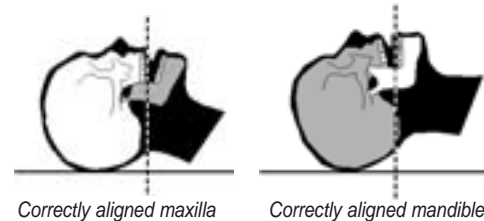
Preparation of the patient

- Remove any non-fixed metal dentures or prosthesis, in addition to any jewelry that might interfere with the region to be scanned. Non-metal dentures may be worn during the scan.
- If the patient has a scan prosthesis**, it should be worn during the scan, as directed by the dentist or surgeon.
- Place the patient supine on the scanner table and move the patient into the gantry, head first.
- Make the patient comfortable and instruct him not to move during the procedure. Normal breathing is acceptable, but any other movement, such as tilting and turning the head can cause motion artifacts that compromise the reformatted images, requiring the patient to be rescanned.

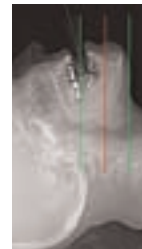
Aligning the patient

- For correct alignment, the transaxial CT slice plane should be parallel to the occlusal plane (see figure). A gantry tilt of 0° is required.
- Ideally, you should determine the occlusal plane using the patient's scan prosthesis. If the patient does not have a scan prosthesis, use the existing teeth to align the patient.

For example, if the patient is edentulous or the occlusal plane cannot easily be determined from the existing teeth, align the transaxial CT slice plane along the ridge of the mandible. Use the head holder with sponges to stabilize the position. If you cannot orient the head properly in the head holder, use the tabletop. In either case, strap the head securely to prohibit motion.



- You can take a lateral alignment image (called a Localizer, Scoutview, Topogram, Scanogram, Pilot or Surview depending on the CT manufacturer) to verify the correct patient positioning.
- Stabilize the relationship of the jaws during the scan. The patient is preferably scanned with the jaws slightly open (if available, you can use a bite block). This will reduce the risk of artifacts from the opposing jaw disturbing the images of the jaw of interest. Also, this will make it possible to isolate the occlusal plane from the images.



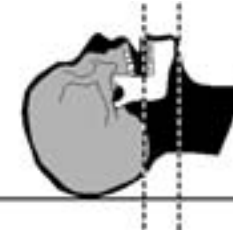
Scanning instructions

Positioning for the mandible

Position the first slice just below the inferior border of the mandible. Position the last slice just above the lower teeth or in the absence of teeth, set the last slice just above the superior border of the mandibular ridge (there should be no bone

in the last slice). If the patient is wearing a scan prosthesis, position the last slice just above the prosthesis. It is critical you include the entire prosthesis in the scanned study and that no teeth or prosthesis are visible in the last slice.

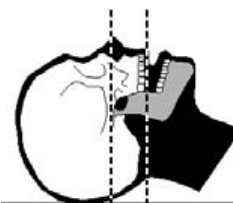
A typical mandible study contains 40-50 axial images spaced at 1.0 mm intervals. Check the first slice before you continue scanning or use a low dose guide slice. The first slice should not contain any bone from the mandible. If you need to scan lower, start again - do not go back and scan slices after you have scanned above the mandibular ridge or the scan prosthesis.



Positioning for the maxilla

Position the first slice just below the upper teeth or in the absence of teeth set the first slice just below the inferior border of the maxillary ridge (the first slice may not contain bone). If the patient is wearing a scan prosthesis, position the first slice just below the prosthesis. It is critical you include the entire prosthesis in the scanned study. Position the last slice 4 to 5 mm above the floor of the nasal cavity, unless otherwise instructed by the referring physician. If it concerns zygoma implants, the last slice must be positioned in the middle of the orbita, called the sutura frontozygomatica.

A typical maxilla study contains 30-40 axial images spaced at 1.0 mm intervals. Check the first slice before you continue scanning or use a low dose guide slice. The first slice should not contain any teeth or prosthesis, or in the case of an edentulous patient should not contain any bone from the maxillary ridge. If you need to scan lower, start again - do not go back and scan slices after you have scanned into the nasal cavity.



General scanning instructions

- Set the table height so that the mandible or maxilla is centered in the scan field.
- All slices must have the same field of view, the same reconstruction center, and the same table height.
- Scanning with a field of view that is too large can compro-

mise the resolution of the reformatted images. Scanning with a field of view that is too small can cause the mandible to not fit in all the axial images.

- Not overlapping the axial slices can reduce the quality of the reformatted images.
- Scan all slices of the study in the same direction.
- Scan with the same slice spacing; the slice spacing must be less than or equal to the slice thickness. The slice thickness should preferably not be larger than 1 mm.
- All of the remaining teeth/scan prosthesis should be completely visible in the images up to the occlusal plane.

Reconstruction of the images

- Use a proper image reconstruction algorithm to get sharp reformatted images where you can locate internal structures such as the alveolar nerve. Use the sharpest reconstruction algorithm available, usually described as a bone or high-resolution algorithm.
- Reconstruct the images with a 512x512 matrix and a field of view that includes the entire arch. We recommend a field of view between 14.0 and 17.0 cm.
- Only the axial images are required, no dental reformatting of the images has to be made.
- The images should be saved in the agreed format and onto the agreed medium (optical disk, CD...) as specified in the scan order. Please send the images to the dentist or directly to Materialise or the service bureau.

Scanning parameters

In conclusion, use the following scan parameters or the closest approximation possible:

Matrix	512 x 512
Field of View	Between 140 and 170 mm
Slice thickness	1.0 mm
Feed per rotation	1.0 mm
Reconstructed slice increment	1.0 mm
Reconstruction algorithm	Bone or high resolution
Gantry tilt	0°



* SimPlant is the merged software of SurgiCase and SIM/Plant

** a scan prosthesis is a radiopaque copy of the temporary teeth setup